

ApiFix Treatment For Adolescent Idiopathic Scoliosis (AIS): The importance of Schroth method exercises after the minimal invasive operation

Nikos Karavidas, MSc, PT

Certified Schroth (BSPTS) Therapist

Certified Schroth Best Practice Therapist

Certified SEAS Therapist

Certified McKenzie Therapist

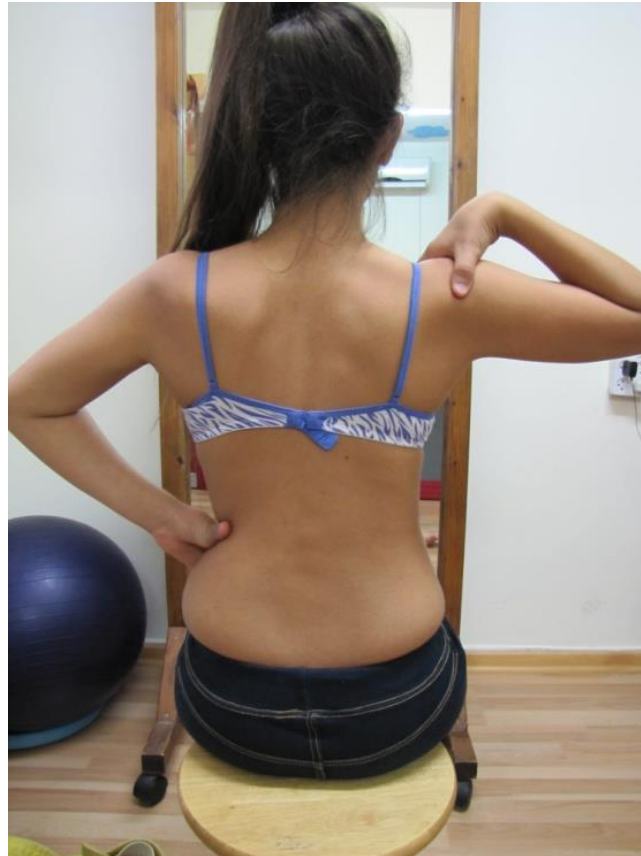MSc Sports Physiotherapy, Cardiff University

I recently signed a contract with the ApiFix Ltd company as their Official Physiotherapist responsible for:

- Developing specific exercises for all the ApiFix patients, according to their type of scoliosis
- Teaching Physiotherapists from other countries on these exercises
- Working with ApiFix patients in Greece and other countries
- Presenting the treatment outcomes in national and international meetings

- Present the short-term results of the ApiFix system in Greece
- Present the necessity of the Physiotherapeutic Scoliosis Specific Exercises (PSSE – Schroth method) pre/post operatively

PSSE



→
 $\leq 25^\circ$

Brace

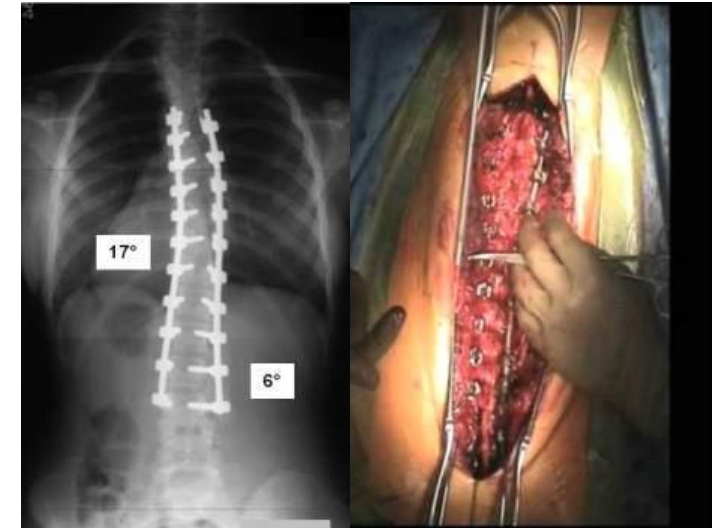


→
 $25^\circ - 40^\circ$

Treatment Severity ↗

ApiFix®

Spinal Fusion

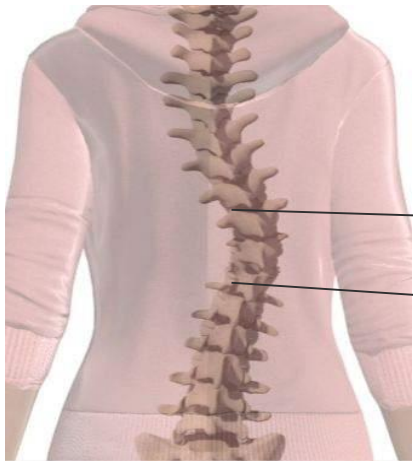

$>45^\circ - 50^\circ$

Nowadays, there is a missing step between conservative treatment and spinal fusion. This gap can be covered (for some cases) by ApiFix, which offers the “internal brace” option



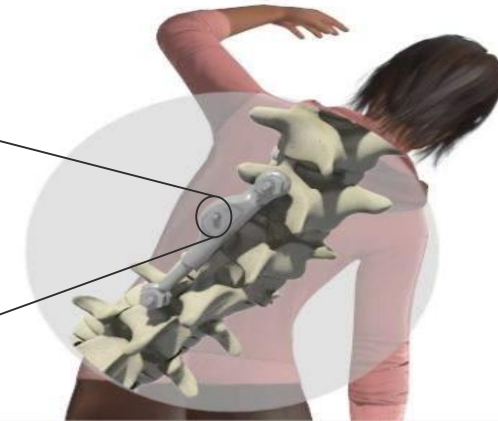
Treatment process




Scoliotic deformity



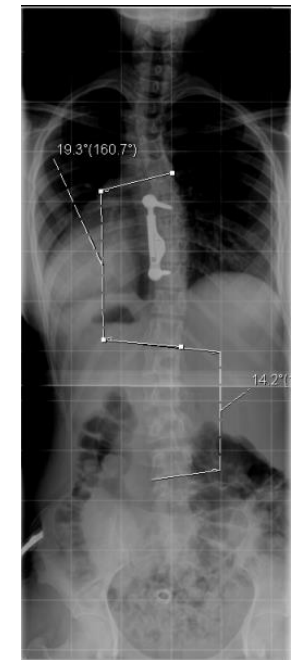
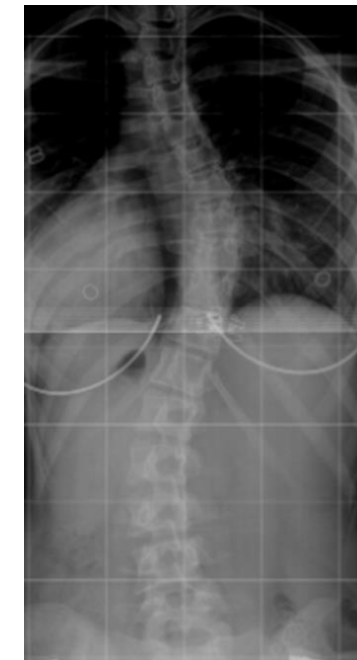ApiFix Implant attaches to the pedicle with 2 screws – peri apical and a relative correction of the deformity is achieved



A miniature ratchet mechanism allows the elongation of an expandable rod

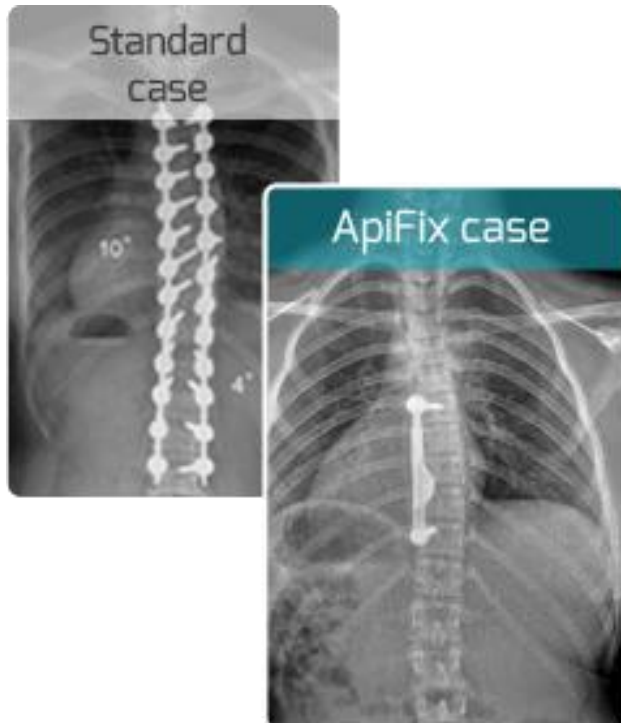


The implant gradually elongates by Scoliosis Specific exercises, enlarging the distance between the two screws. This gradual correction targets to bring the curvature into the “safe zone”, below 30°



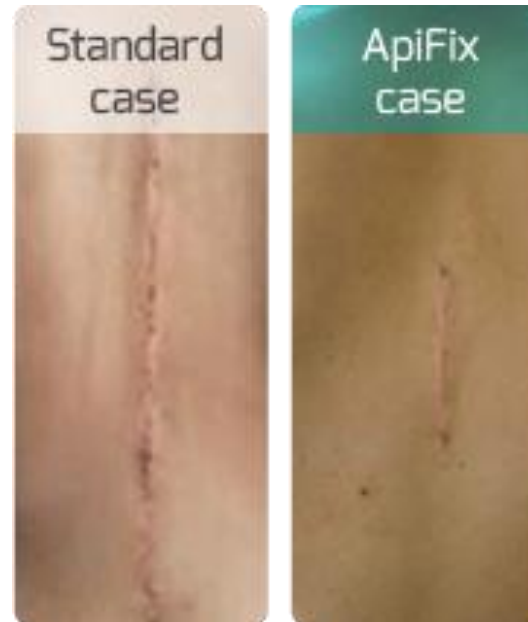Spinal fusion

- Surgical incision approx. 30- 45 cm
- Duration of operation 6-8 hours
- Hospitalization 6-7 days
- Blood loss 800-1500cc



ApiFix

- Surgical incision approx. 10 cm
- Duration of operation 45-60 min
- Hospitalization 1-2 days
- Blood loss 50 cc
- No fusion, no effect on growth plates, does not affect growth
- Normal range of motion of spine after surgery
- Potential option to remove the device after maturity
- Option for spinal fusion in the future



- ApiFix is not applied to every type of scoliosis
- Lenke type 1 (Main Thoracic), Lenke type 5 (Thoracolumbar)
- Cobb angle 40° – 60°
- Moderate rotation
- Flexible curve
(significant correction in side-bending x-rays)

<u>Lumbar Spine Modifier</u>	Curve Type (1 - 6)					
	Type 1 (Main Thoracic)	Type 2 (Double Thoracic)	Type 3 (Double Major)	Type 4 (Triple Major)	Type 5 (TL/L)	Type 6 (TL/L - MT)
A (No to Minimal Curve)	1A*	2A*	3A*	4A*		
B (Moderate Curve)	1B*	2B*	3B*	4B*		
C (Large Curve)	1C*	2C*	3C*	4C*	5C*	6C*
Possible Sagittal structural criteria (To determine specific curve type)	Normal	PT Kyphosis	TL Kyphosis	PT + TL Kyphosis		

- : <10°
 * T5-12 sagittal alignment modifier: -, N, or + N : 10-40°
 + : >40°

Pre-operation

- Curvature classification
- X-ray evaluation and estimation of Cobb angle
- Evaluation of flexibility by lateral bending x-rays
- **Start of PSSE approx. 1 month pre-op**
- Improve body awareness, flexibility and mobility

Post-operation

- Exit of the hospital 1-2 days after the operation
- **Re-start of PSSE 2 weeks post-op**
- Regular radiological assessment
- Continuation of the exercises for at least 6 months
- Open the ratchet mechanism, further improve of correction, improve posture, ADL training, stabilization of secondary curvatures, pain and function management

General goals of treatment:

- **Personalized and curve pattern specific exercises (Physiotherapeutic Scoliosis Specific Exercises- PSSE)**
- **Based on 3D auto-correction, self elongation and Activities of Daily Living (ADL) training**
- Cobb angle and Angle Trunk Rotation (ATR) improvement
- Improvement of posture and clinical appearance
- Reduction or elimination of pain
- Improvement of spinal mobility and flexibility
- Improvement of Vital Capacity (VC) and breathing function
- Reduction of mechanical forces that promote progression



The exercises must be prescribed only by Schroth Certified Therapists



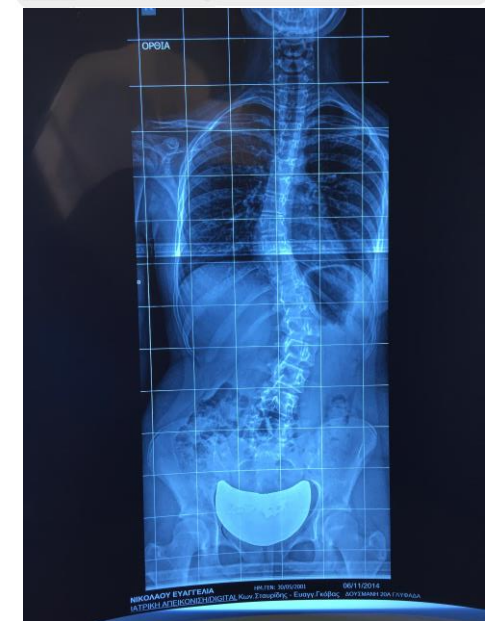
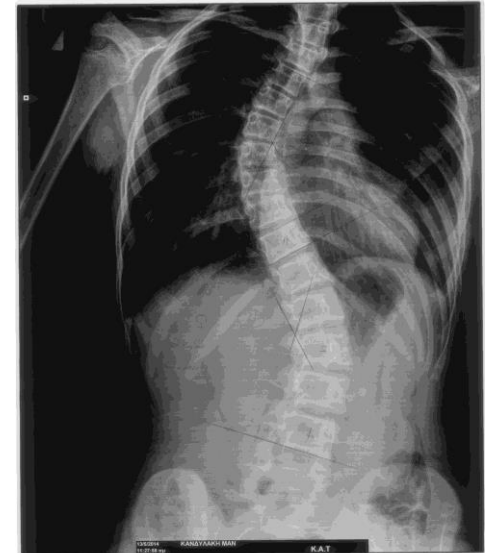- Prospective on-going study
- 10 female patients
- Mean age 15.3 years, Risser sign 3.9, Cobb angle 46°
- Scoliosis Specific Exercises program for 6 months post-op (at least) with Schroth method
- **Outcome parameters: Cobb angle, Angle Trunk Rotation (ATR), Aesthetics (TAPS – TRACE), Pain (VAS)**
- Average follow-up 17.5 months
- Unpaired student t-test for statistical analysis

Results

Age	Risser	Cobb pre-op	Cobb post-op	Cobb change	% correction
19	5	37	23	14	37,8%
15.5	4	30	6	24	80,0%
14	0	54	35	19	35,2%
17	5	59	39	20	33,9%
14	4	40	23	17	42,5%
14	4	37	28	9	24,3%
16	5	54	37	17	31,5%
14	3	52	29	23	44,2%
15	4	53	18	30	66,0%
15	4	44	27	17	38,6%
15,3	3,9	46,0	27,0	19,0	42,4%

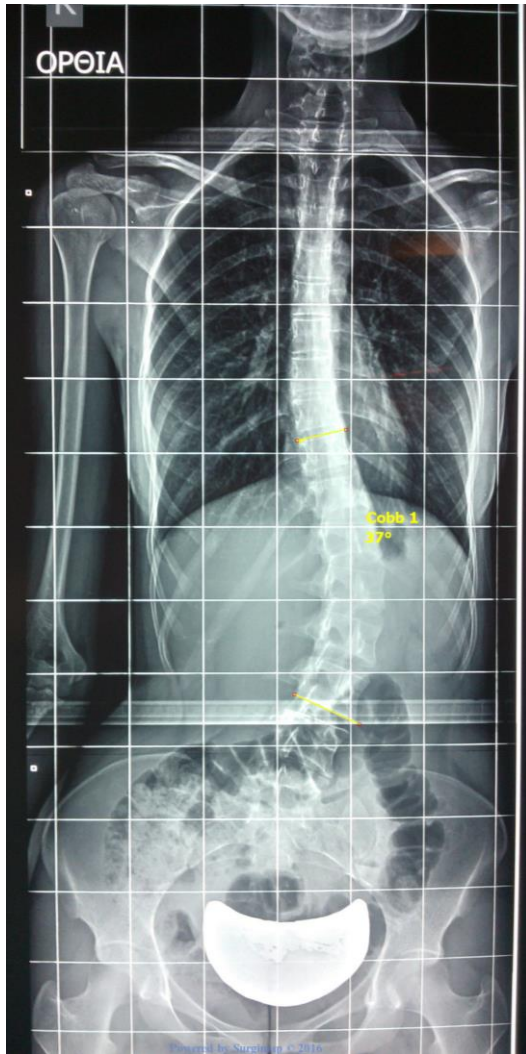
Significant Cobb angle reduction (42.4%, p= 0.012)

- Better results compared with previous research from Israel (avg Correction 32%)
- Not clear indication for ApiFix in many patients
- **Complications:** (1/10 patients) 2 Revision operations, 1st) positioning of the screw 2nd) backup of the ratchet that was corrected by locking the mechanism
- **Limitations:** 2 patients with functional/movement deficits post-operatively (both Lenke 3, ApiFix lumbar), some improvement by exercises
- 2 patients still have some pain/numbness after operation (both non-compliant with exercises)
- 1 patient improper length of mechanism (24.3% correction), excluded from pre/post ex. analysis

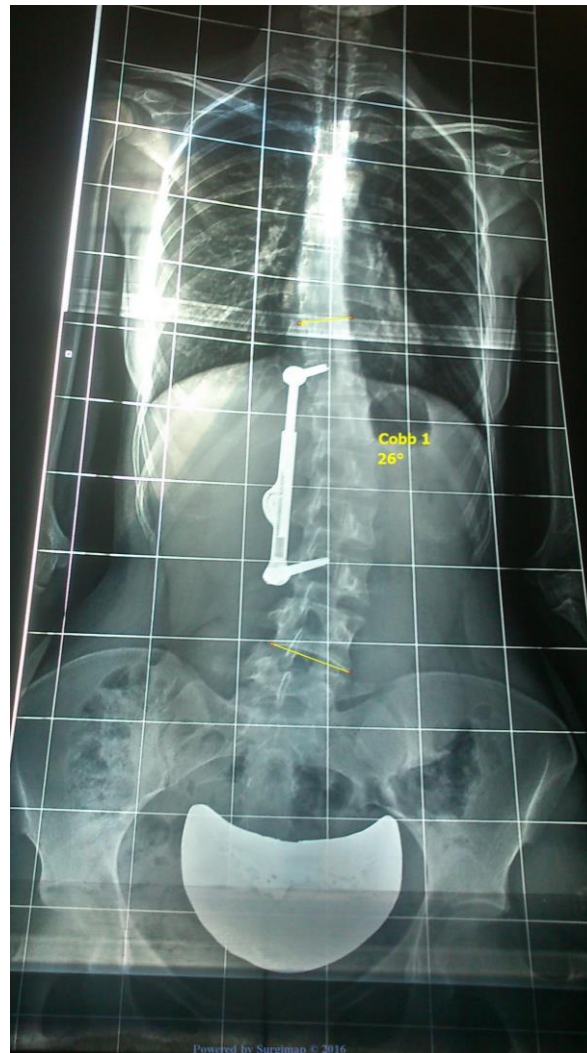


- 6 patients analyzed (following Schroth ex. for minimum 6 months)
- **Cobb** angle improvement by **4.6°** (from 26.3° to 21.7° , p= 0.53)
- **ATR** improvement by **2.3°** (from 10.5° to 8.2° , p=0.252)
- **TAPS** score improvement by **0.7** (from 3.2 to 3.9, p=0.113)
- **TRACE** score improvement by **2** (from 3.75 to 1.75, p=0.001)
- Pain score(**VAS**) improvement by **1.3** (from 2 to 0.7, p=0.11)

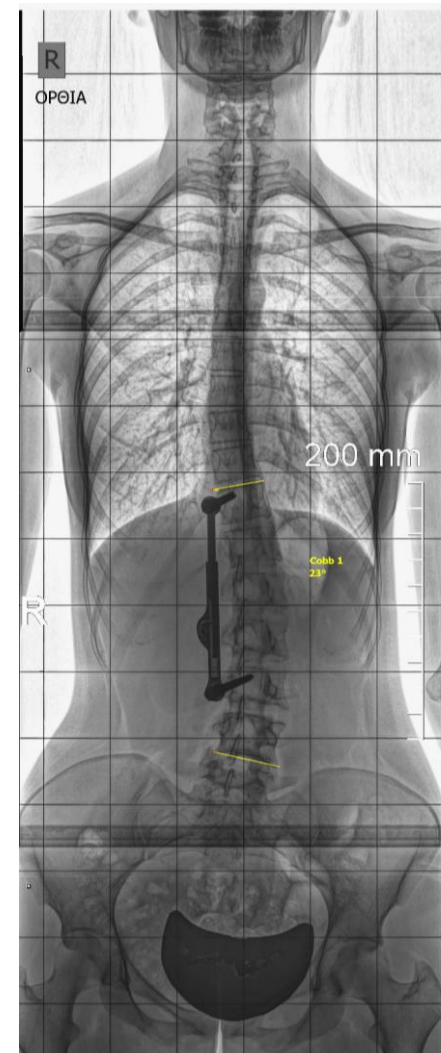
Case study 1



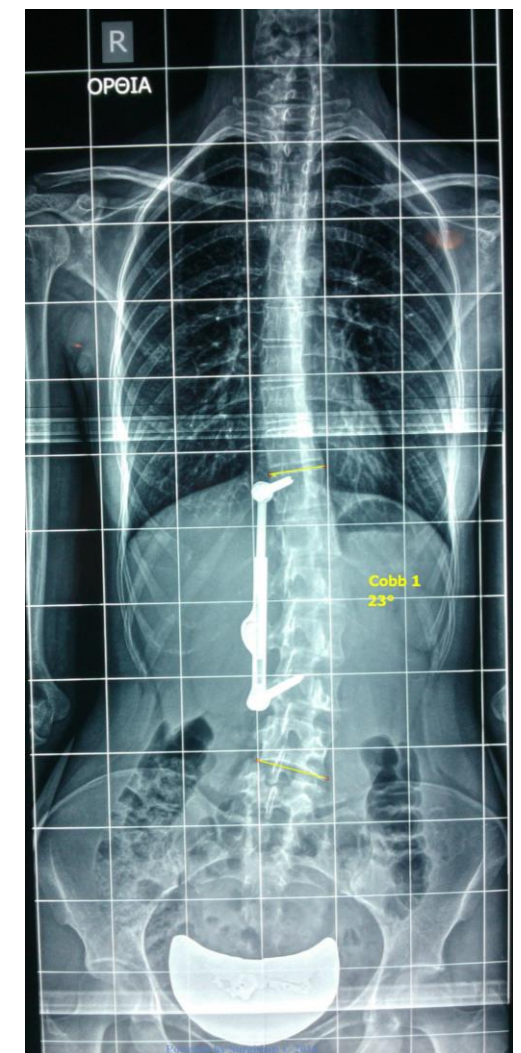
pre-op
Lu (L) 37°



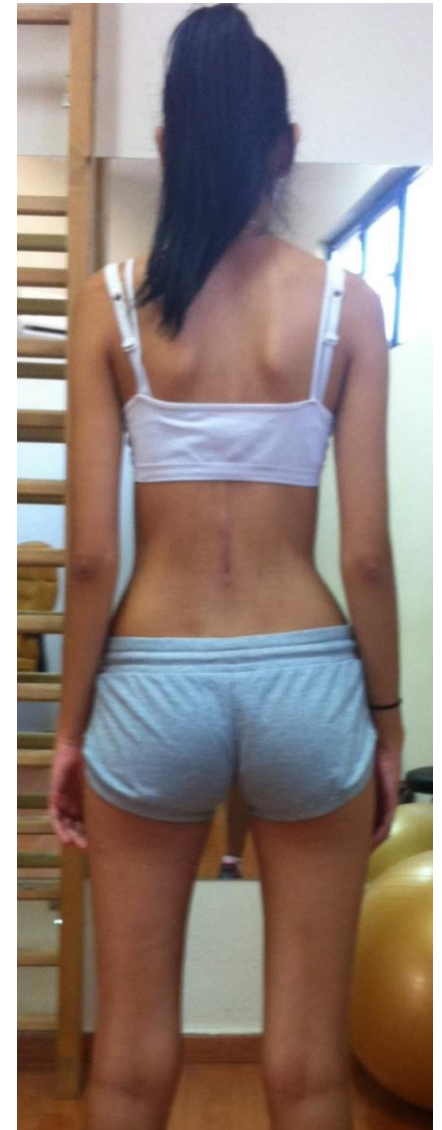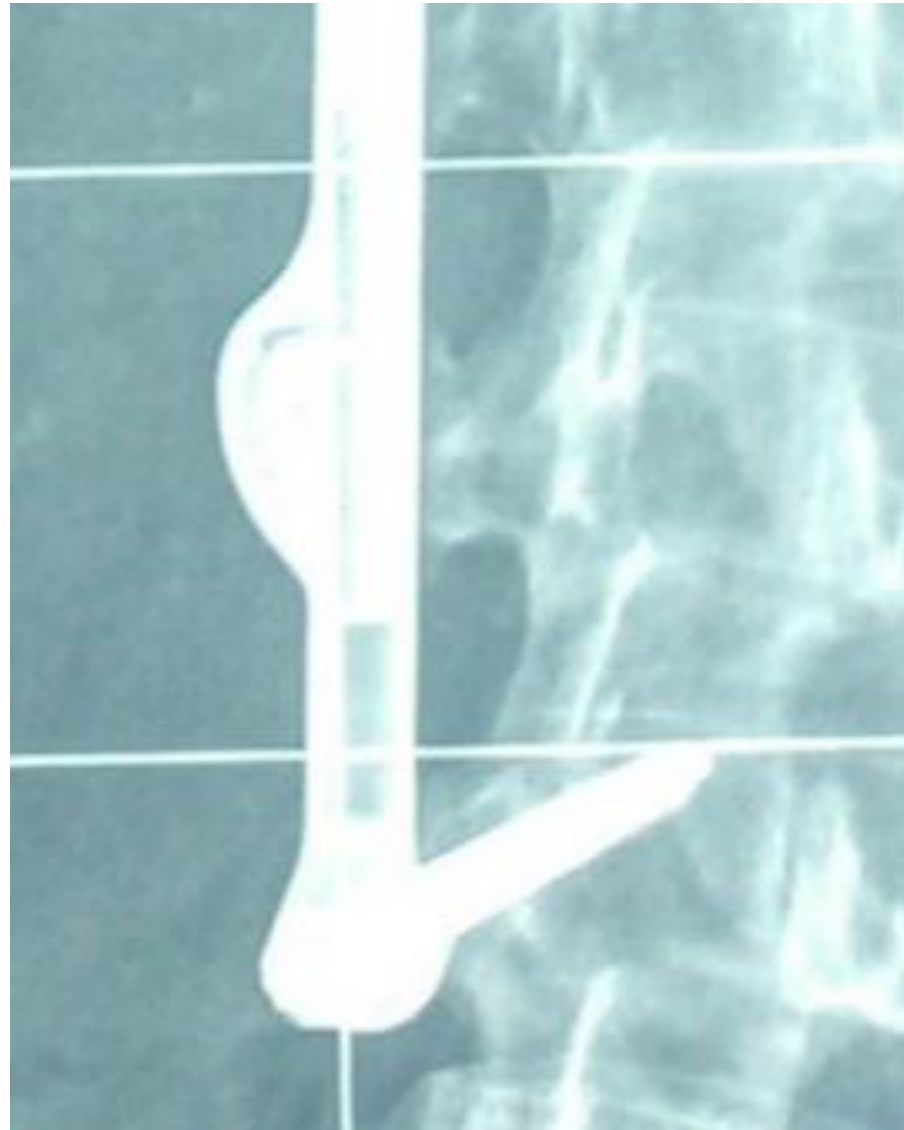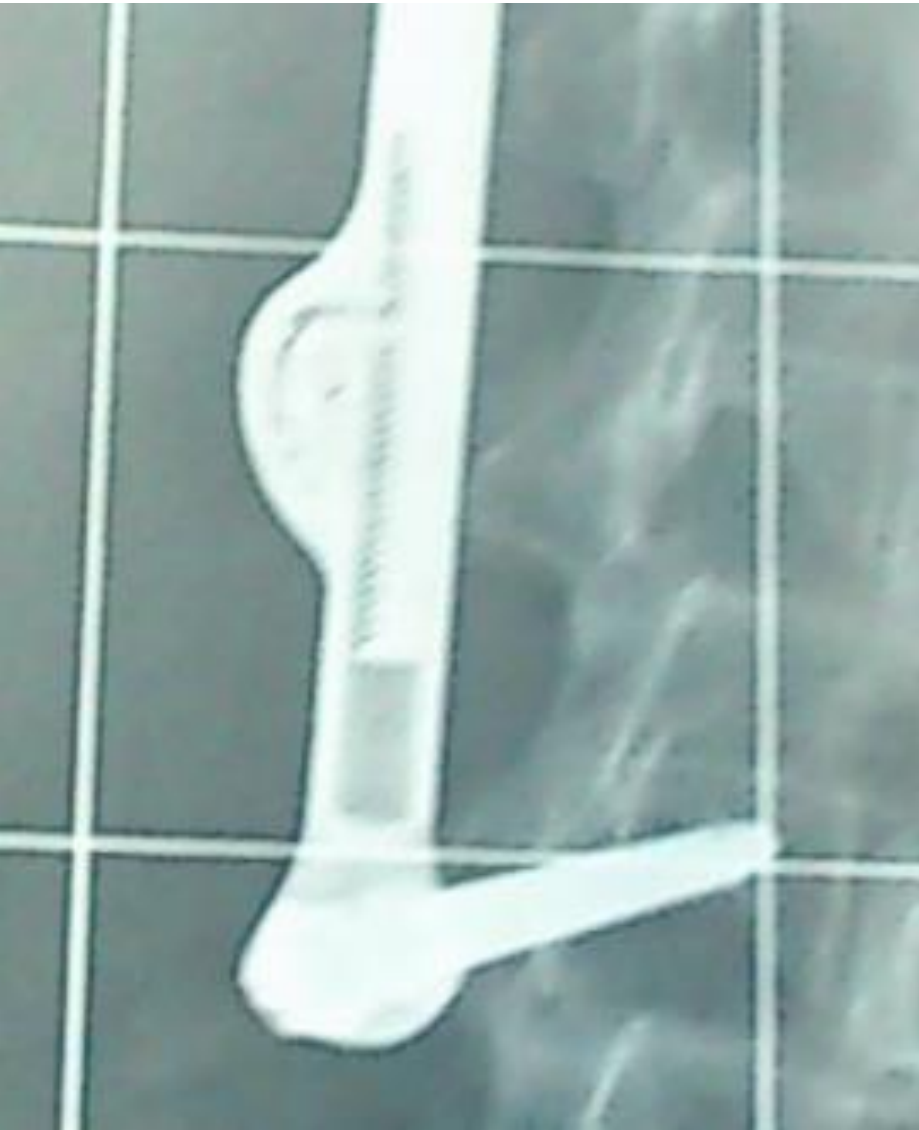2w post-op (no exerc.)
Lu (L) 26°

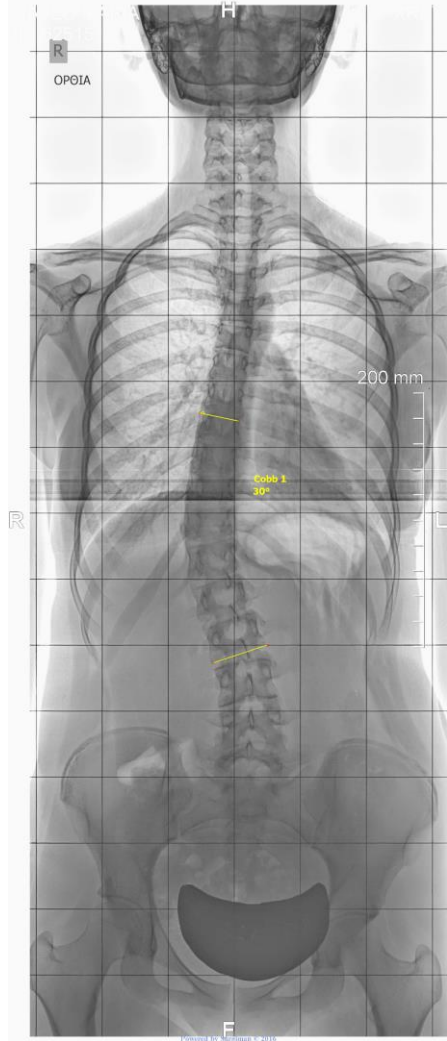


6m post-op
Lu (L) 23°

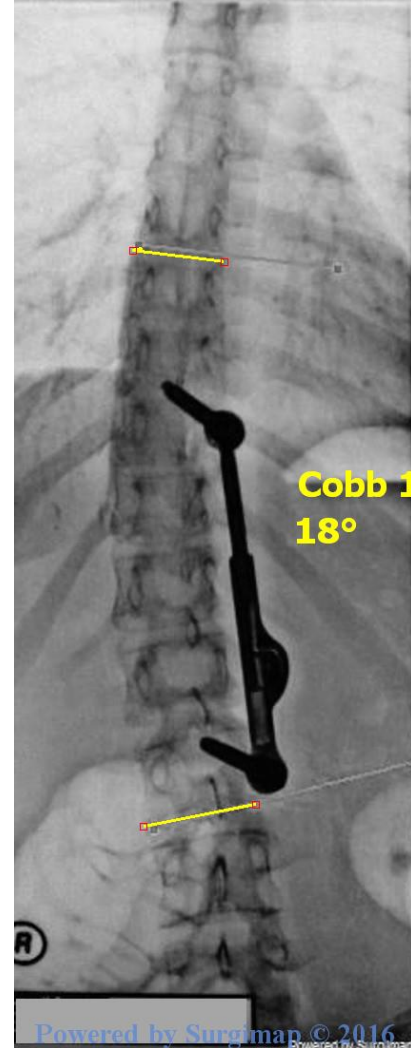

2y post-op
Lu (L) 23°

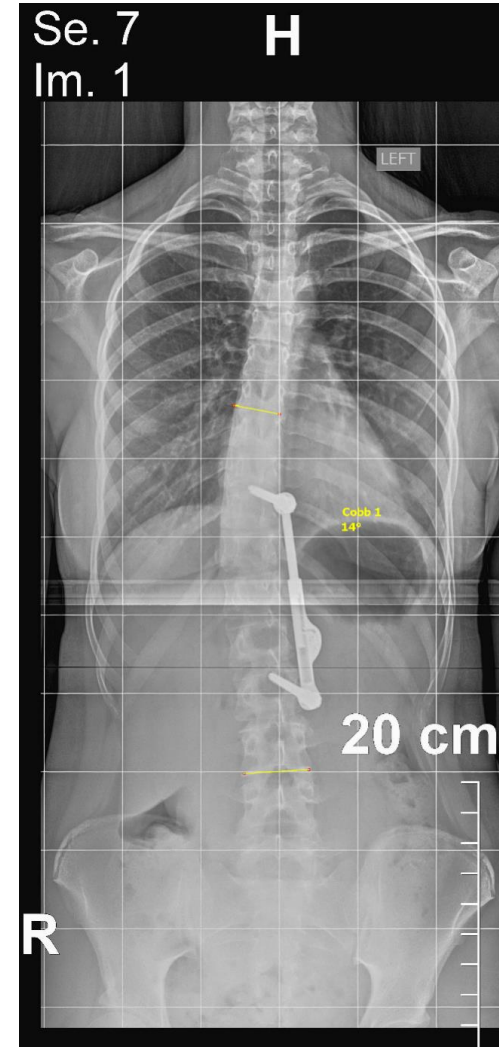




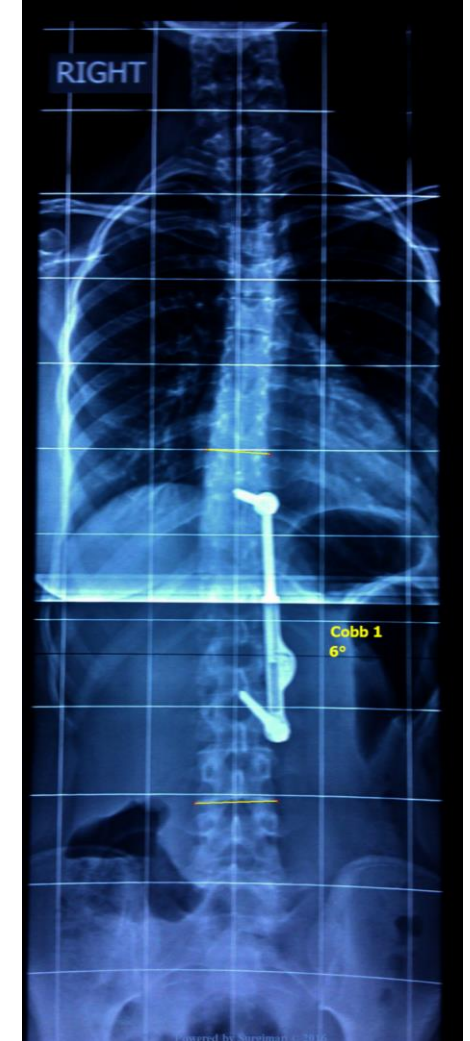pre-op
Th-Lu (R) 30°



2w post-op (no exerc.)
Th-Lu (R) 18°

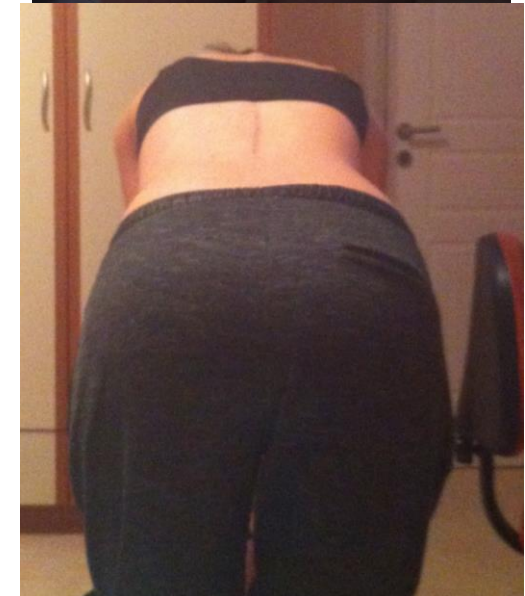
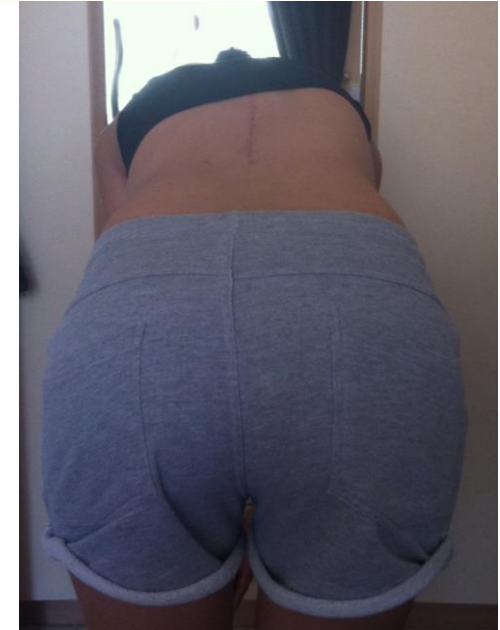
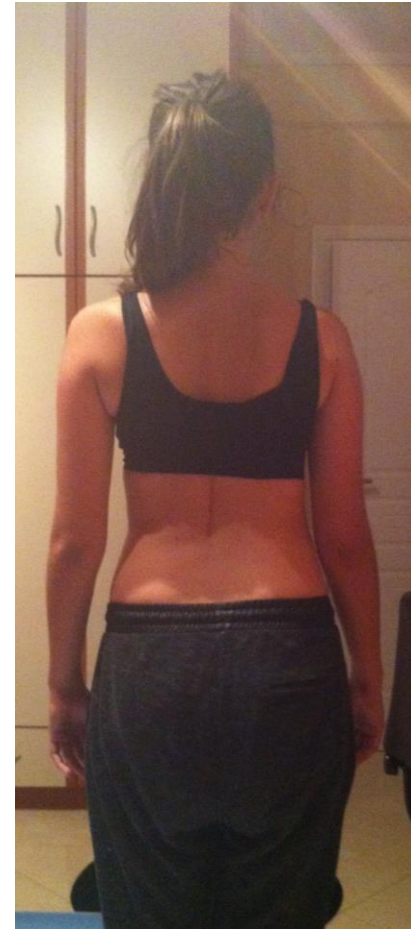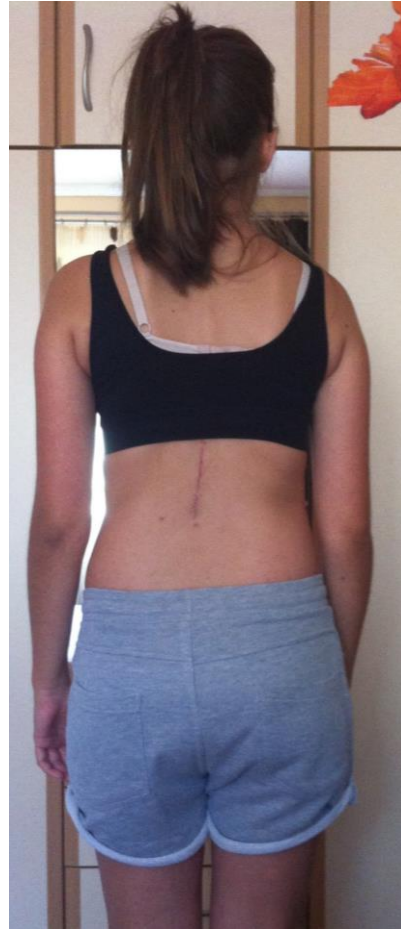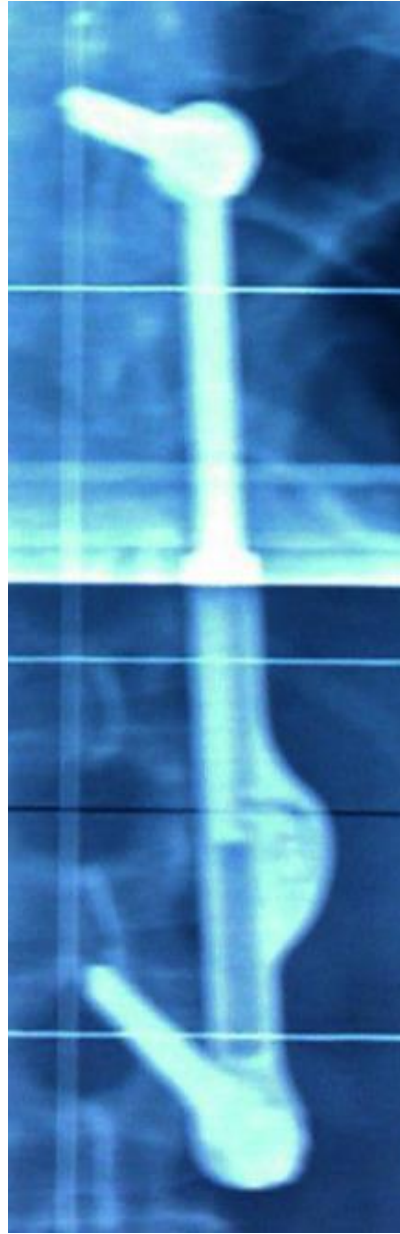
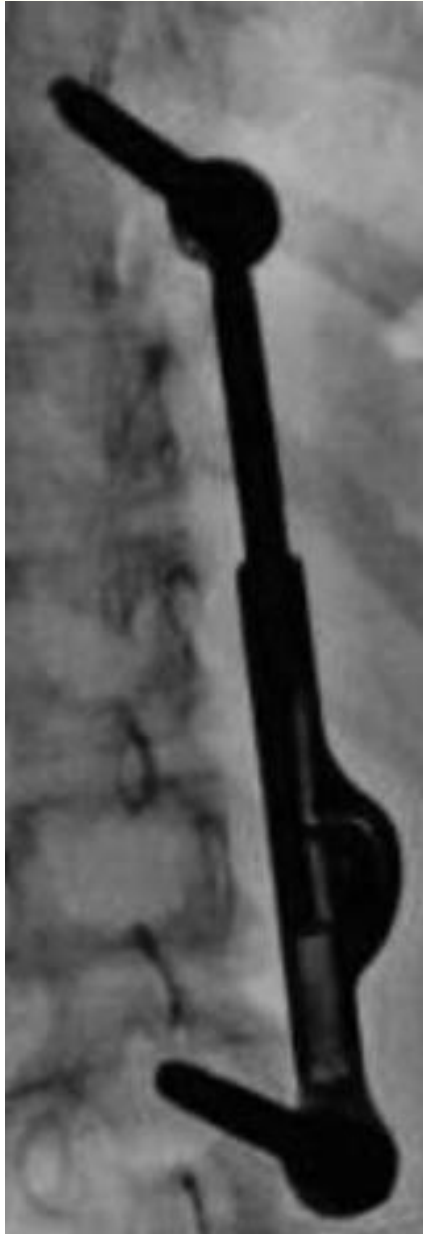


6m post-op
Th-Lu (R) 14°

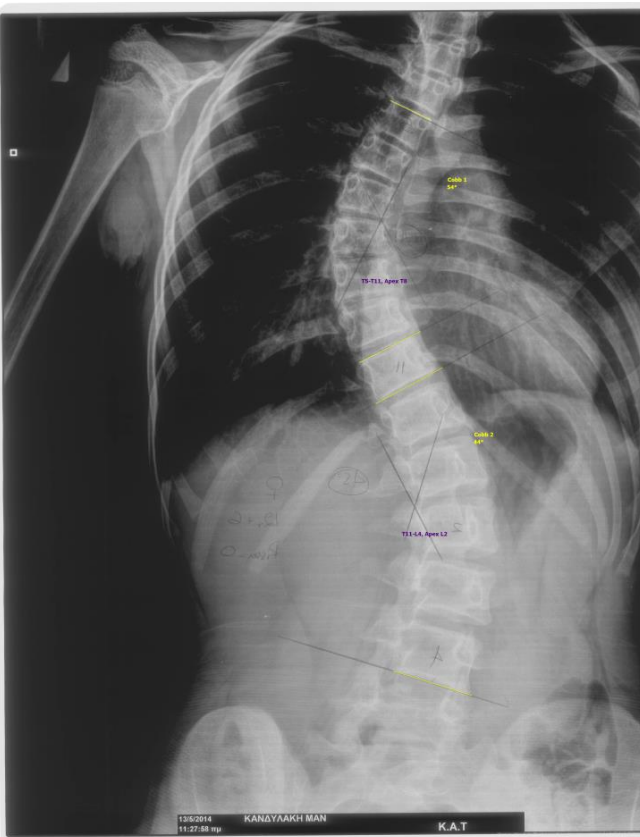


18m post-op
Th-Lu (R) 6°

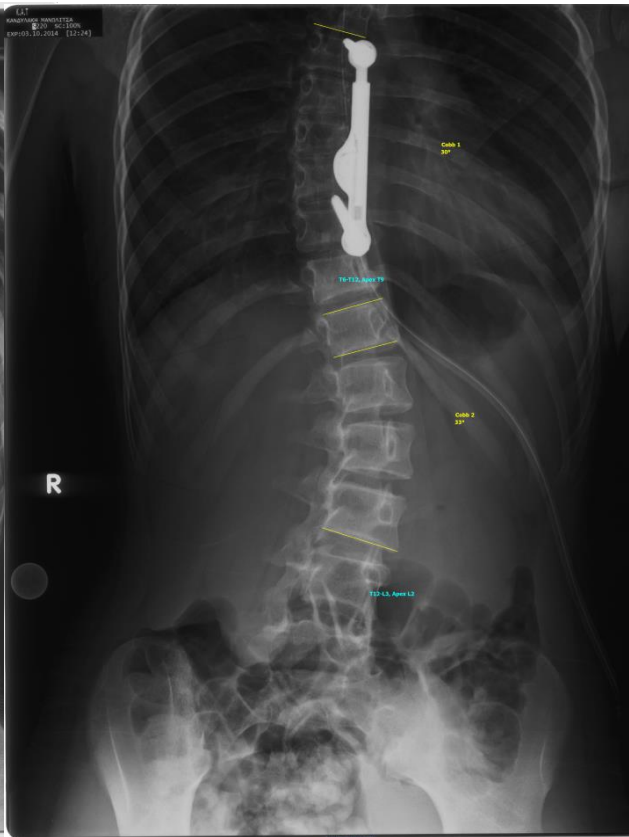
Case study 2



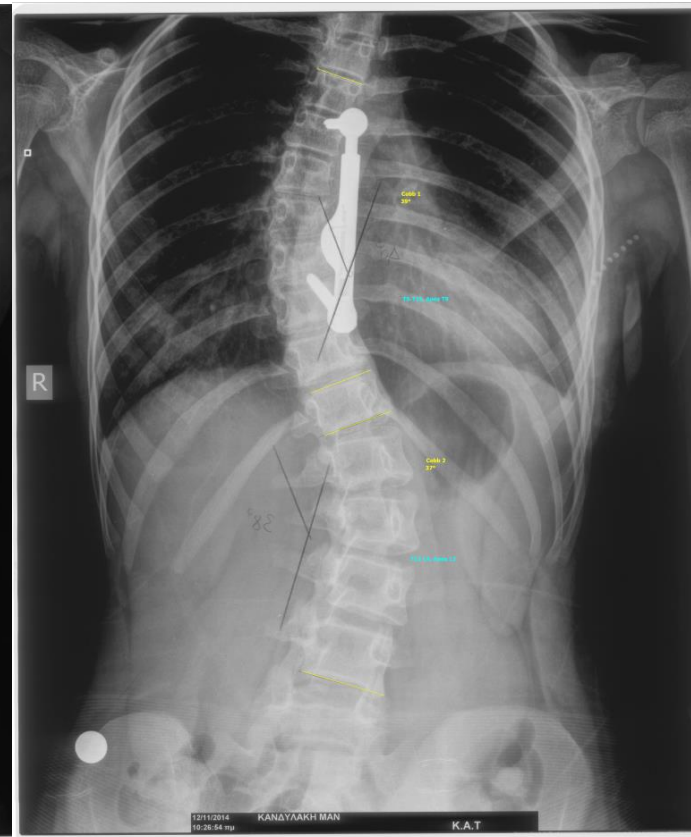
Case study 3



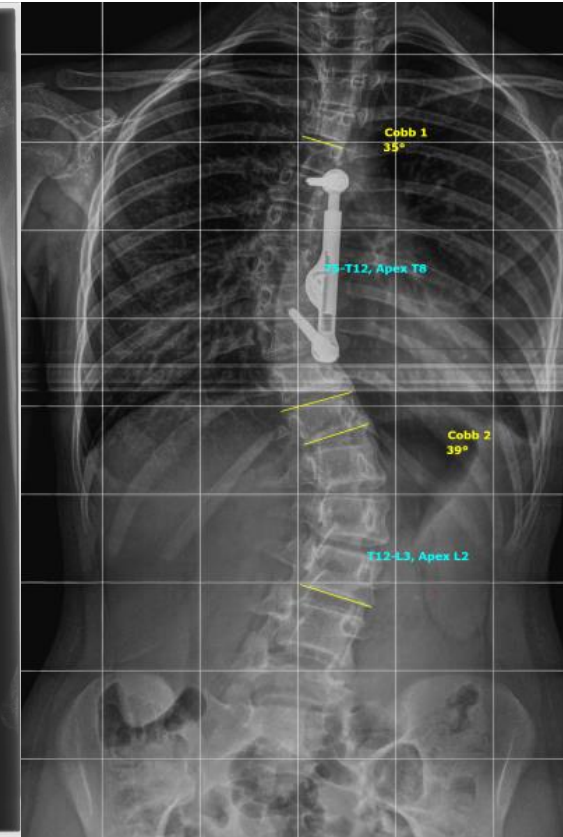pre-op
Th (R) 54° – Lu (L) 44°



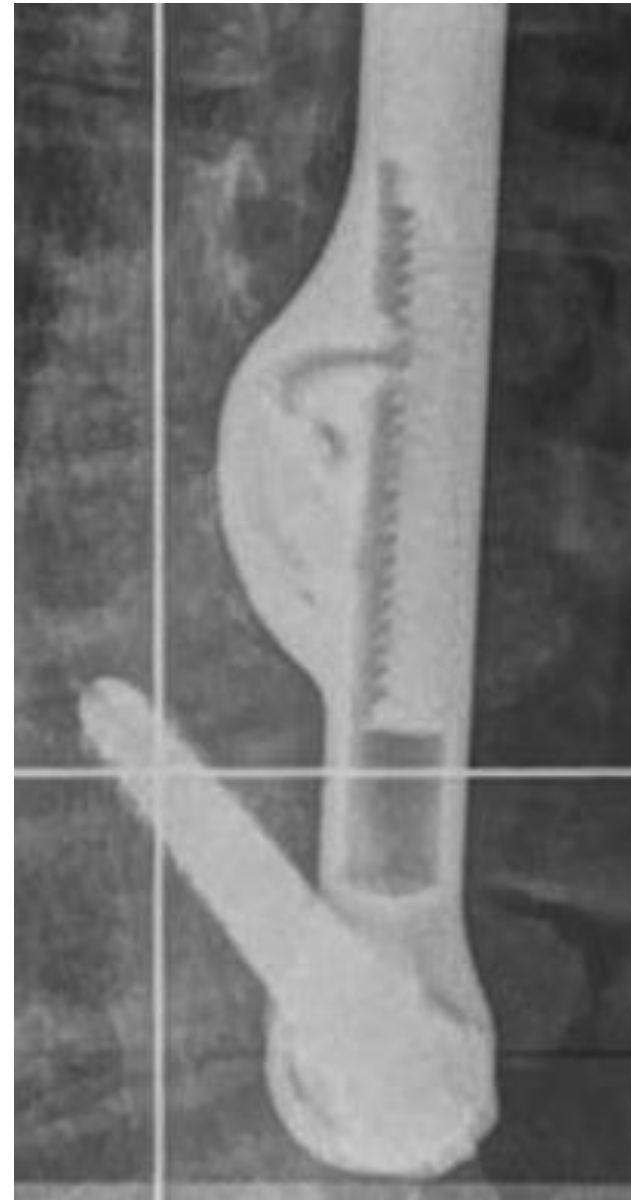
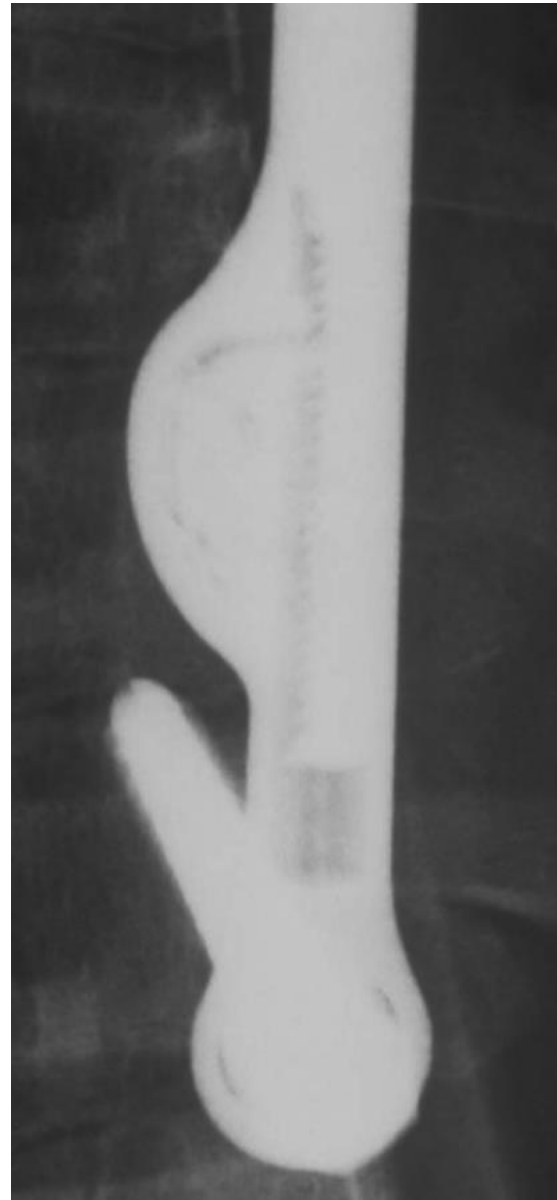
1d post-op
Th (R) 30° – Lu (L) 33°



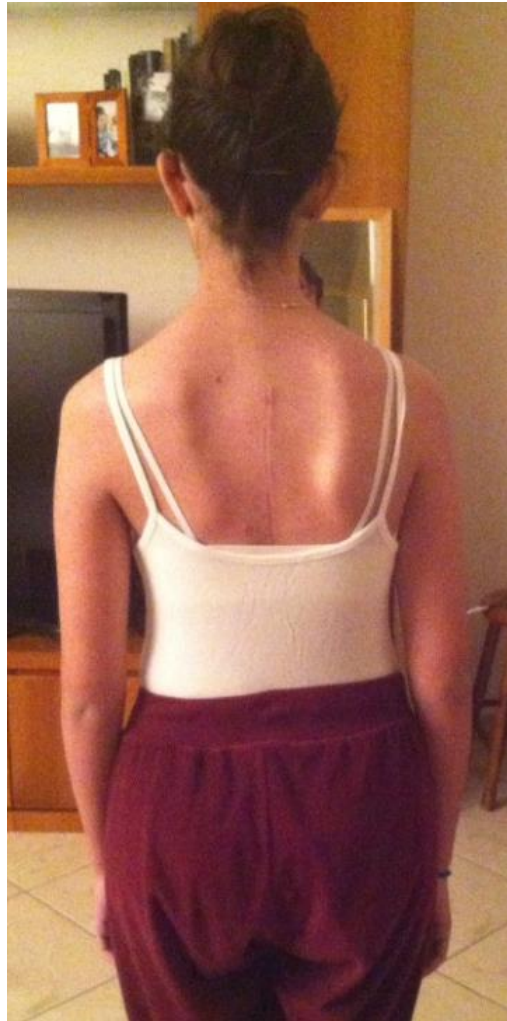1m post-op
(before exercises)
Th (R) 37° – Lu (L) 39°



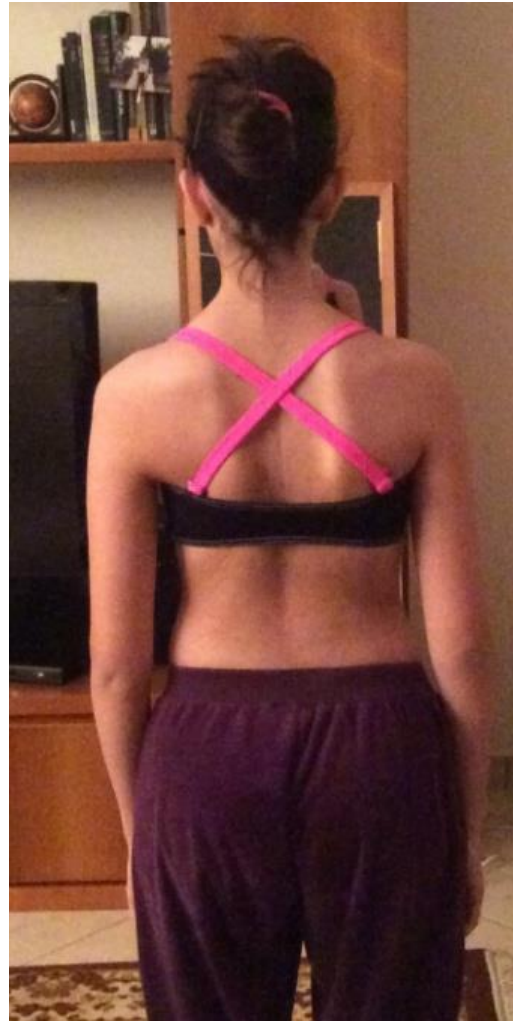6m after
Schroth exercises
Th (R) 35° – Lu (L) 39°



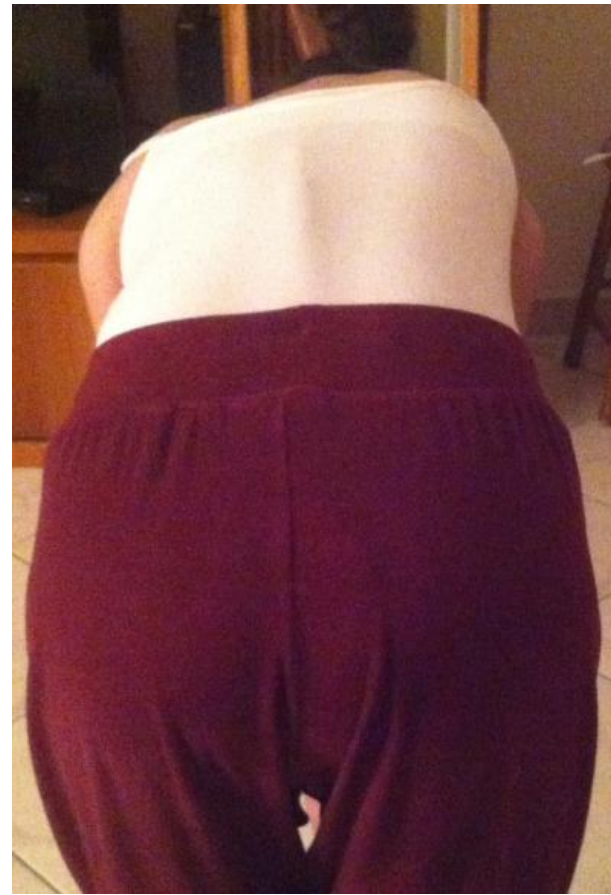Clinical appearance improvement (shoulders, pelvic asymmetry, ATR) after Schroth exercises



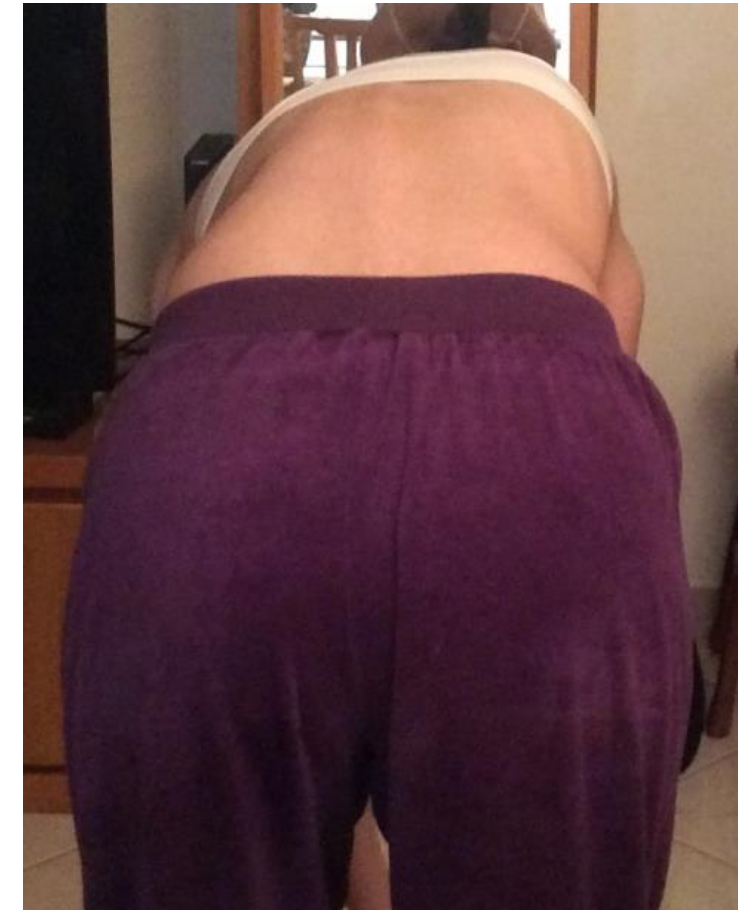Before Schroth ex.



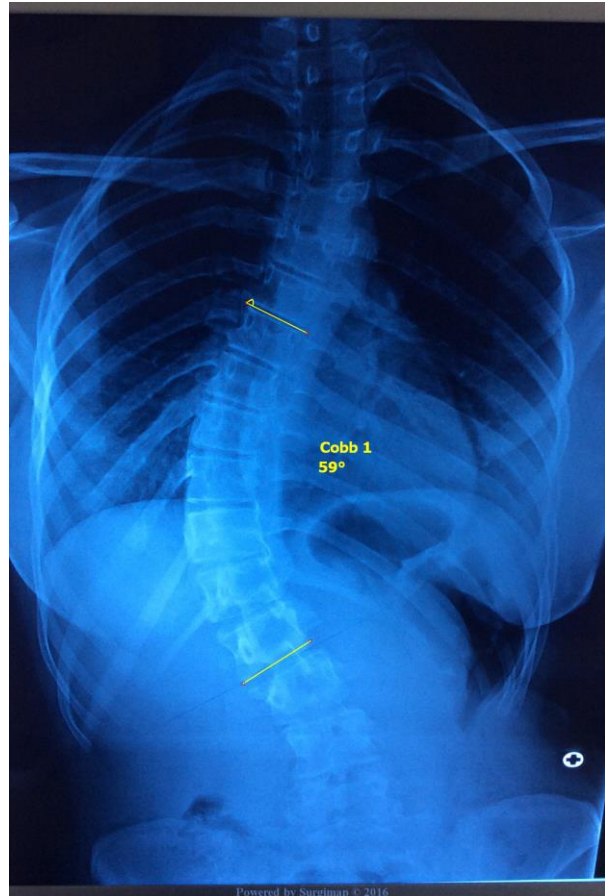
6 months after Schroth ex.



Before Schroth ex.

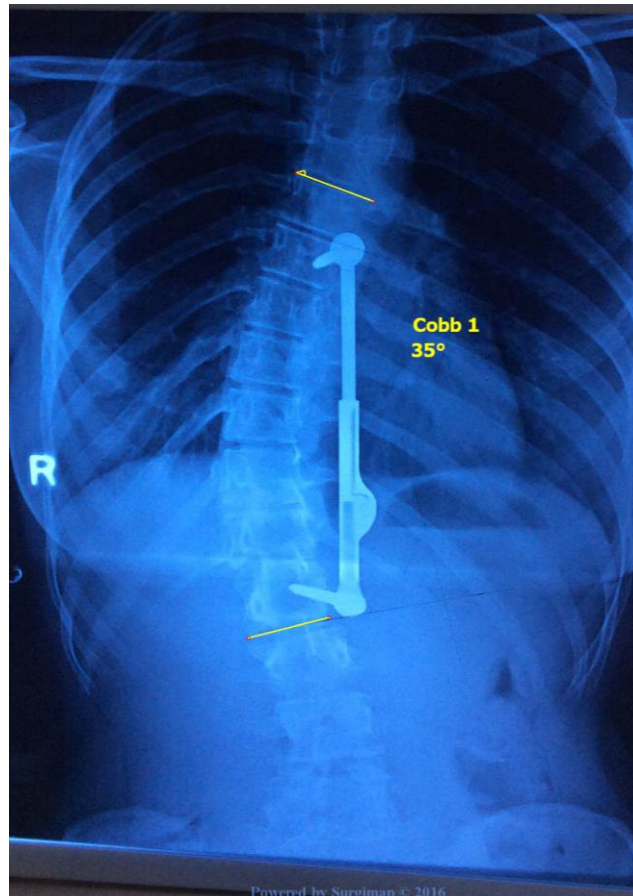


6 months after Schroth ex.



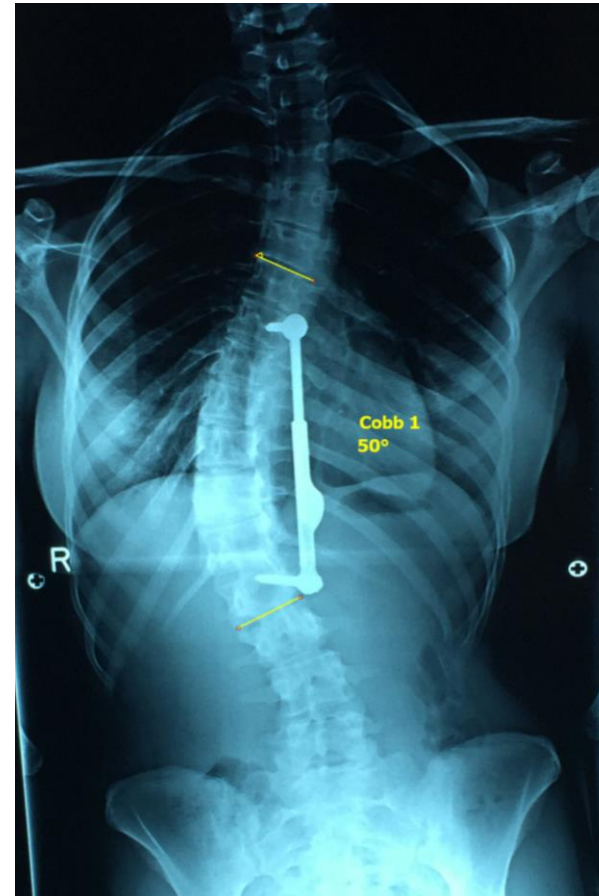
pre-op

59°



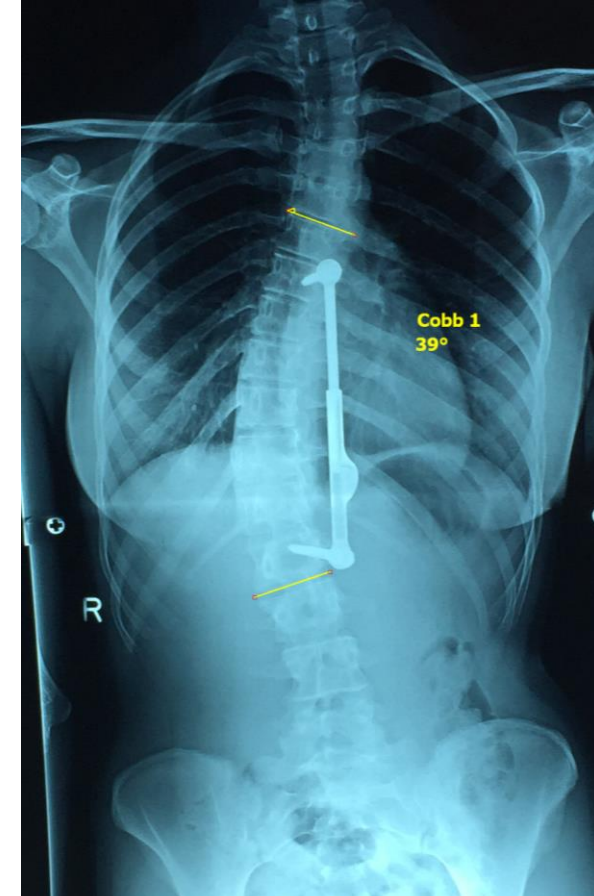
3m post-op

35°



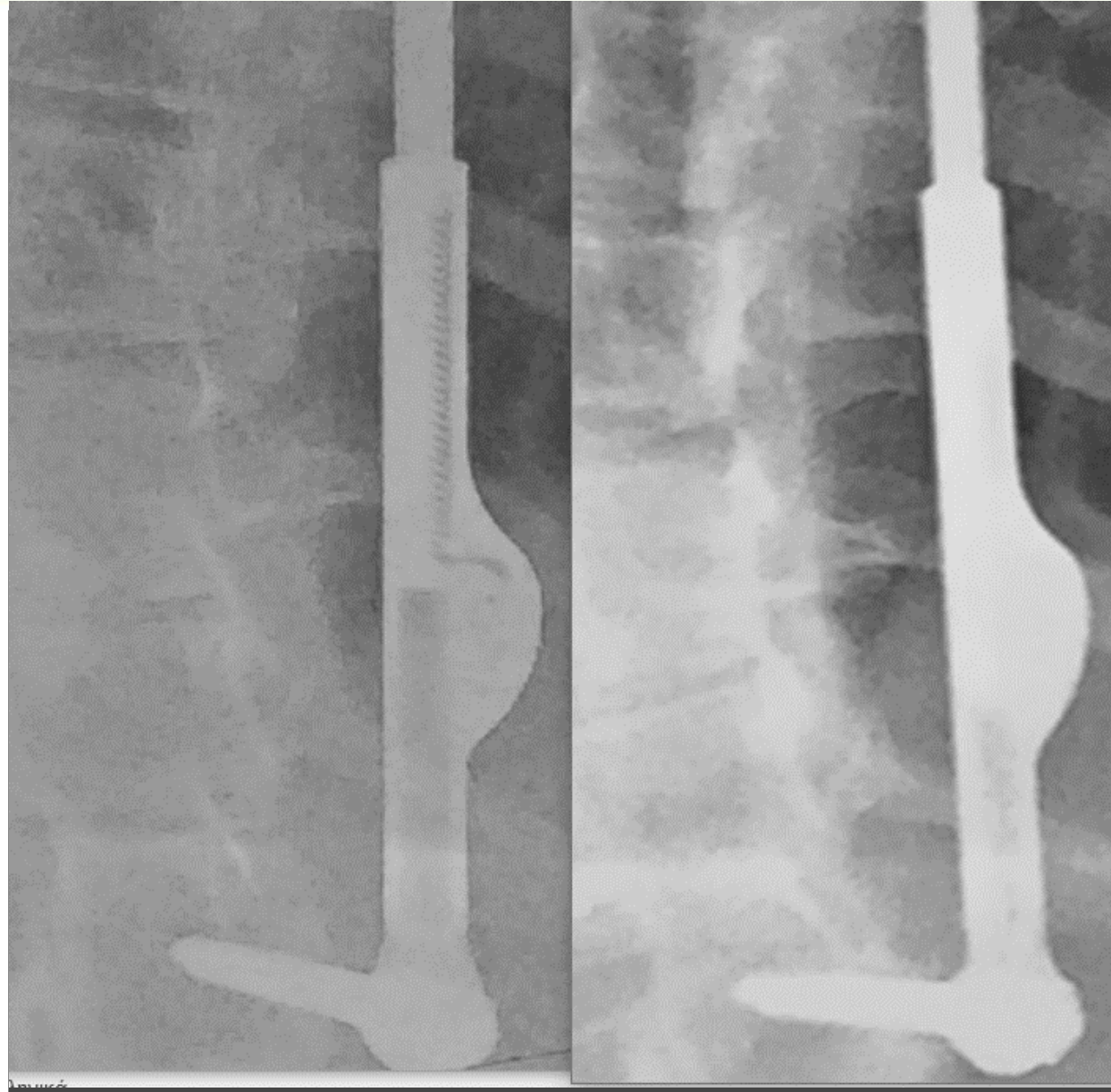
6 m post-op (before revision)

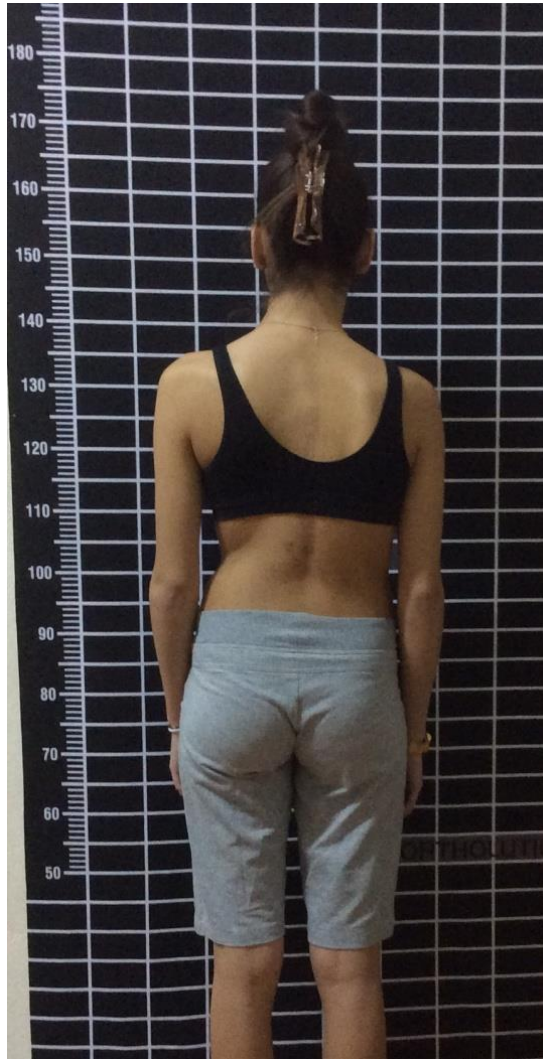50°



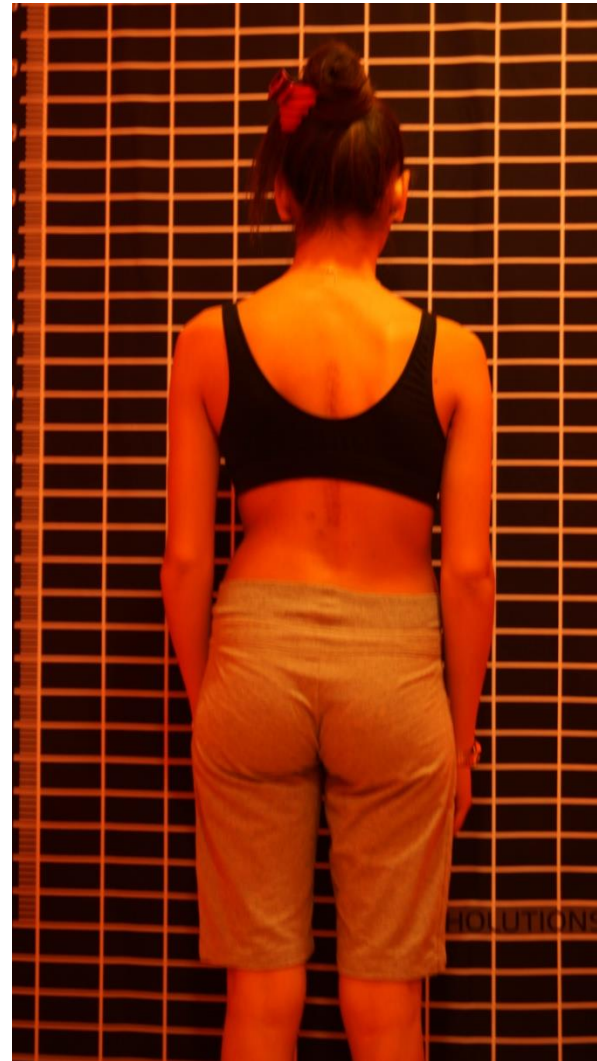after revision surgery

39°





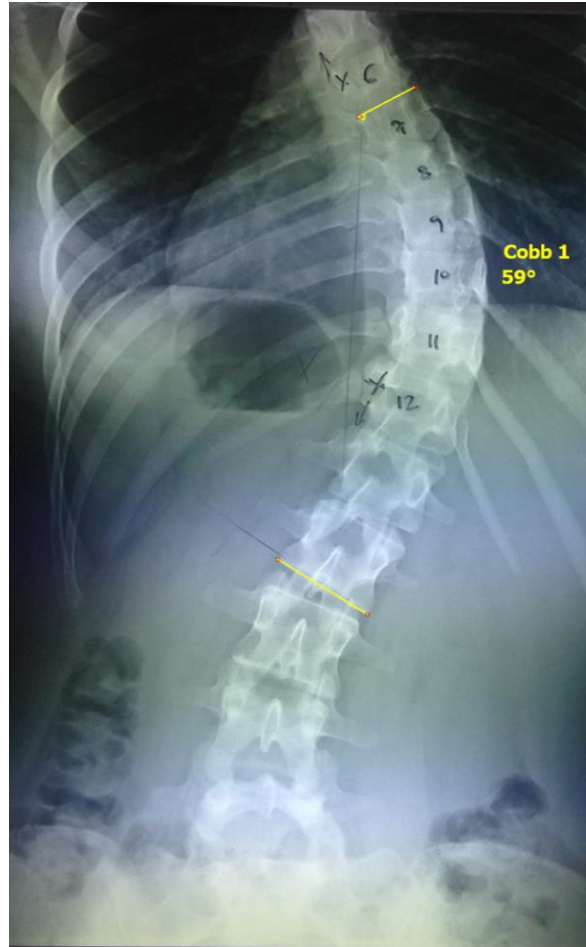post-op/pre-ex



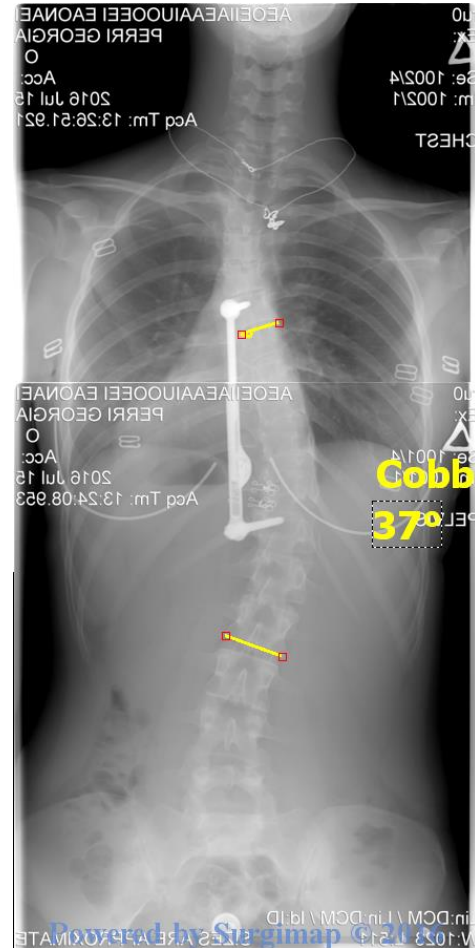
3m post-op



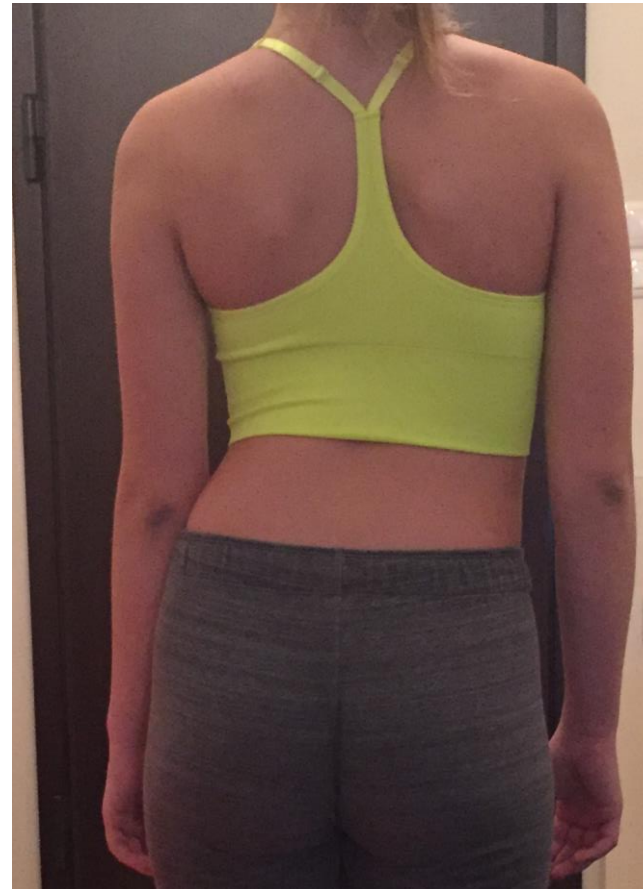after revision surgery



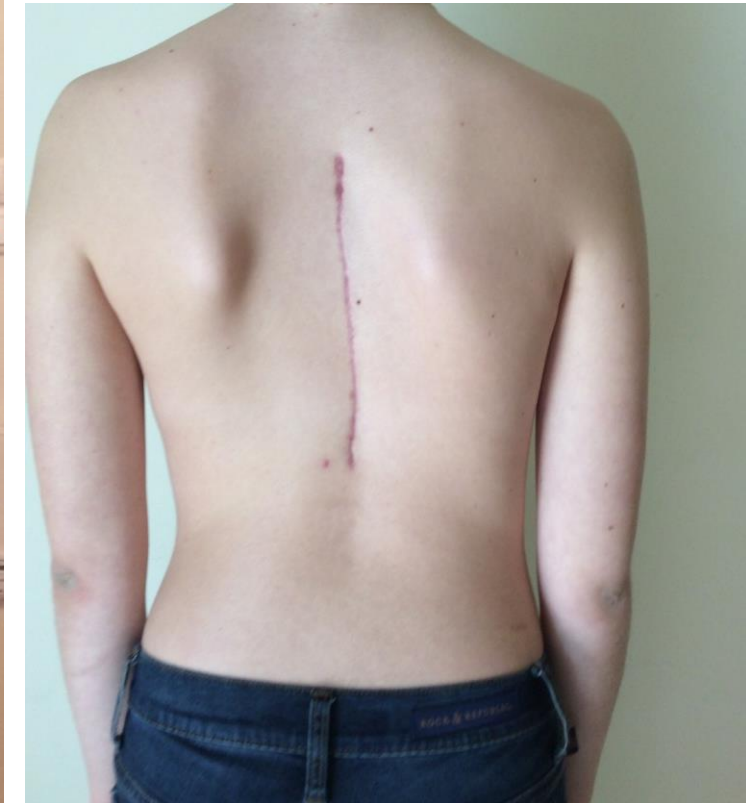Pre-op
59°



post-op
37°



Pre-op



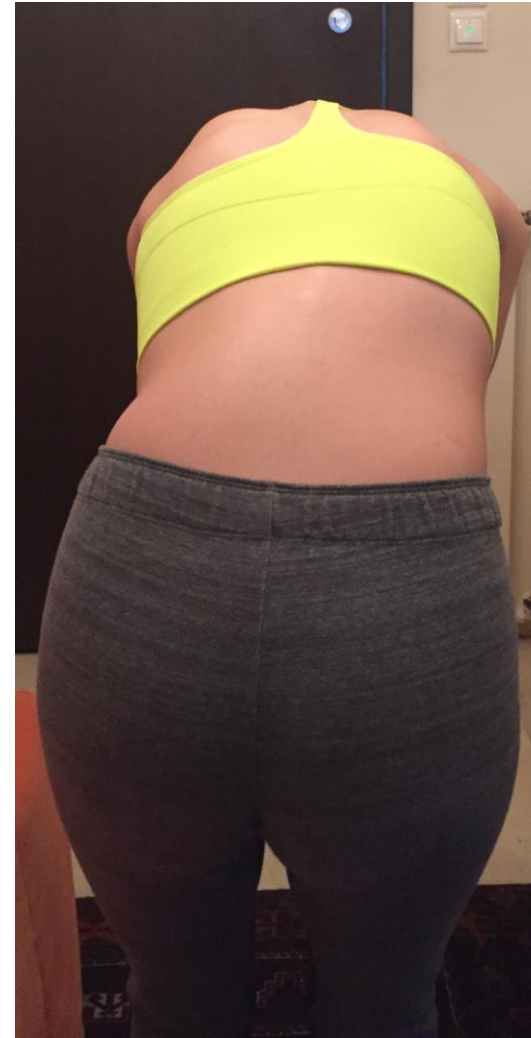6 months post-op



Pre-op



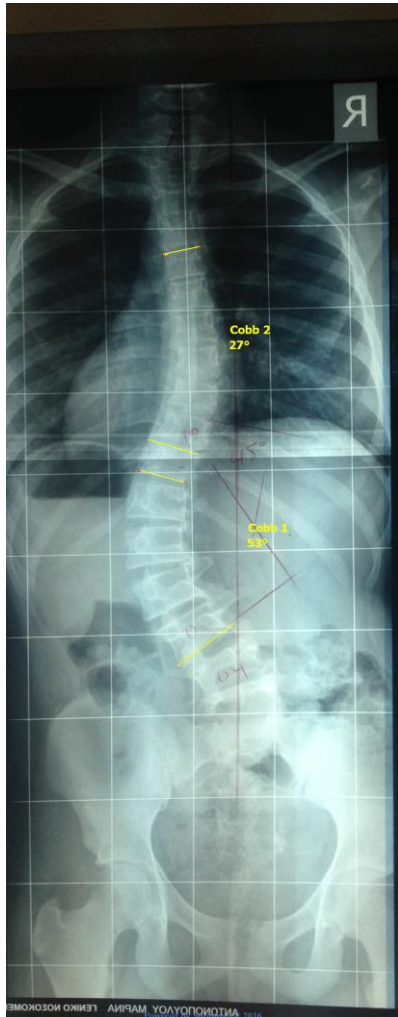6 months post-op



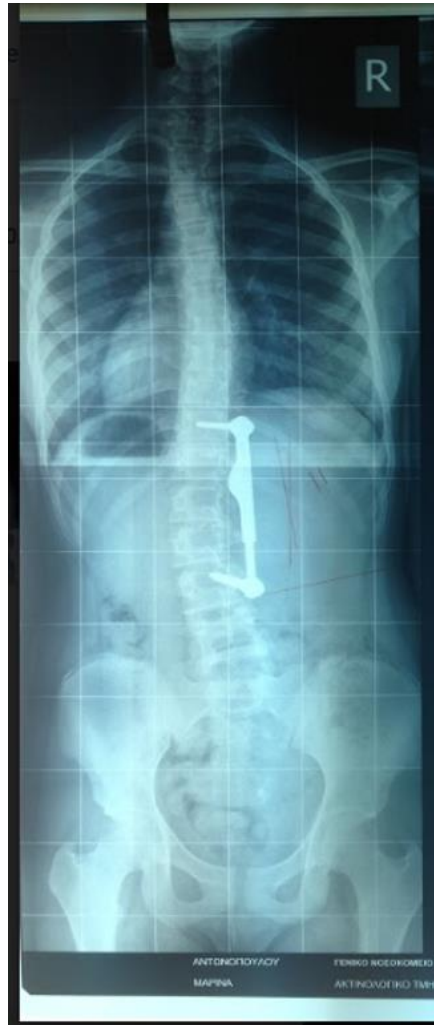Pre-op



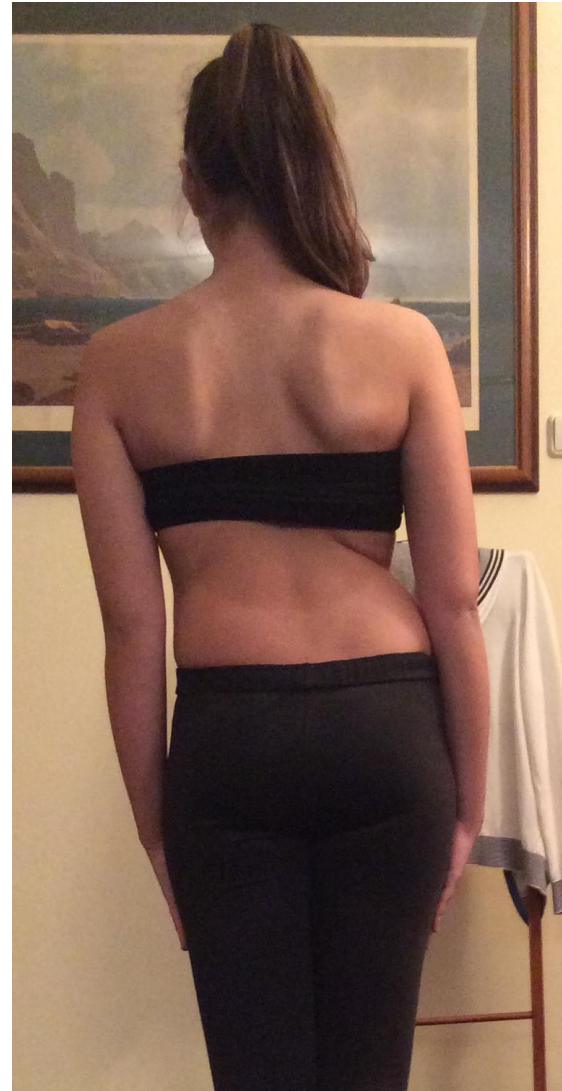
6 months post-op



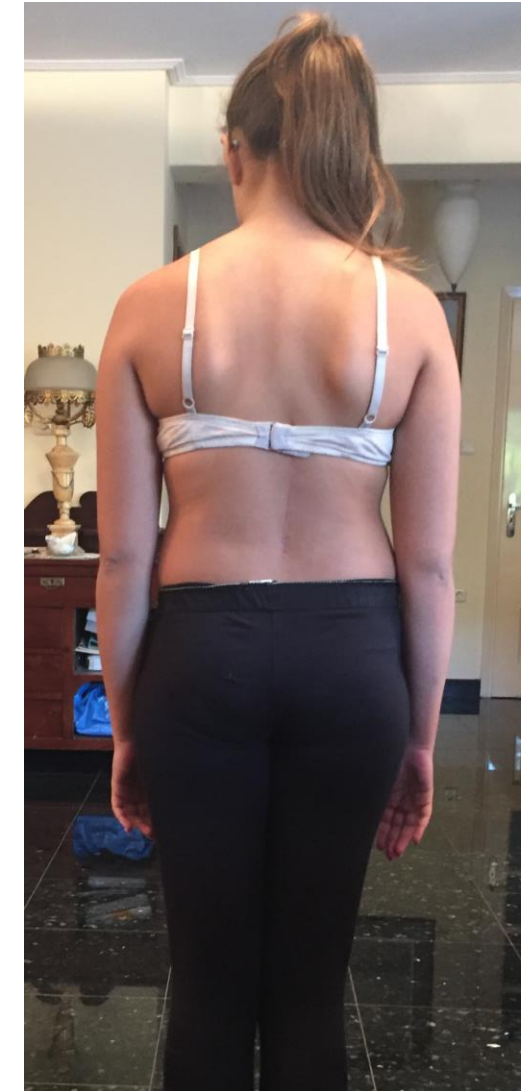
Pre-op
53°



post-op
16°

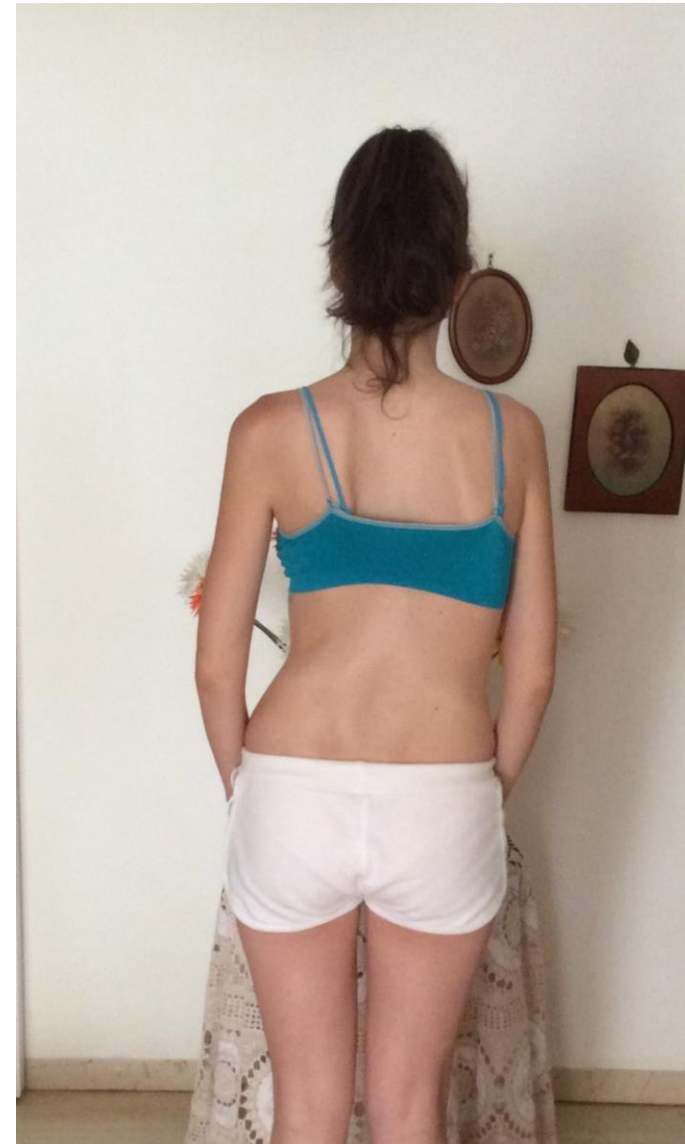
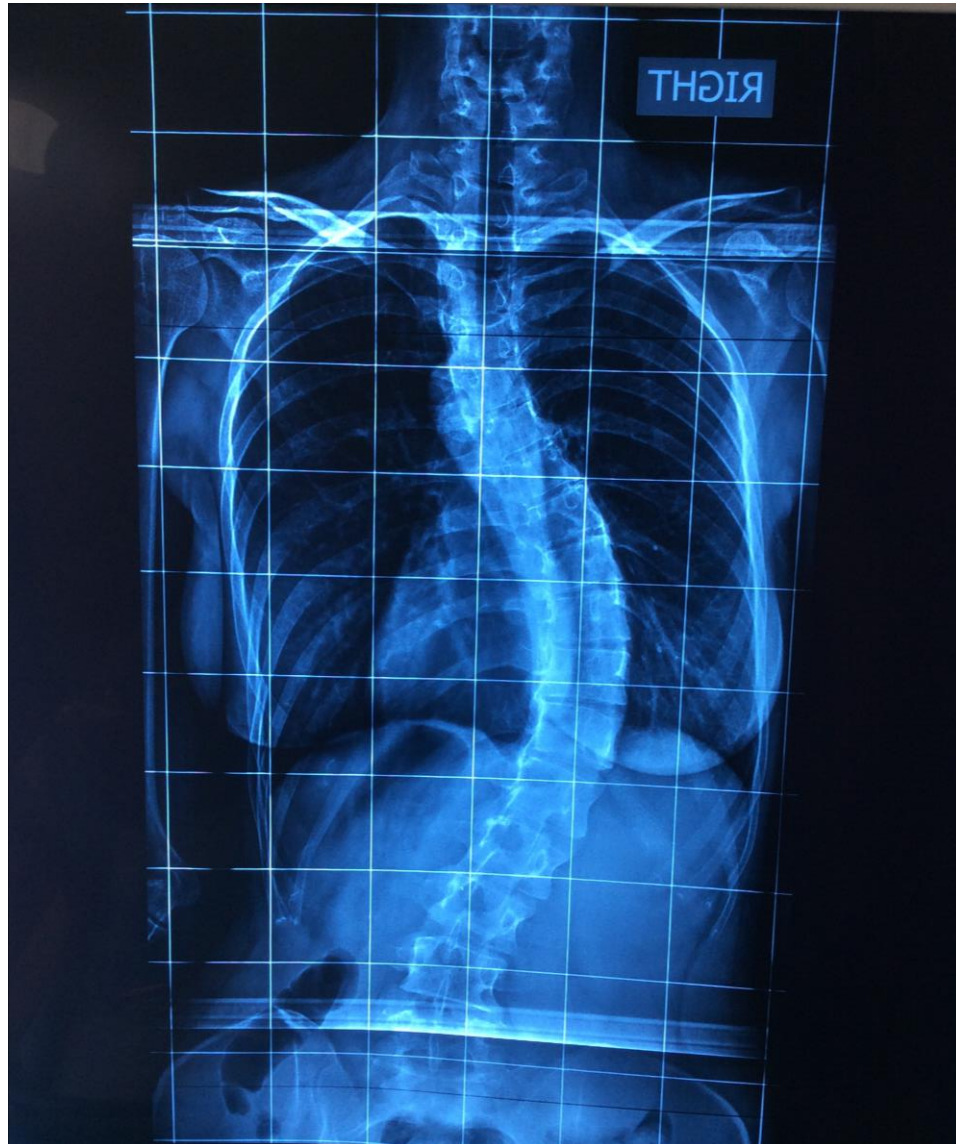
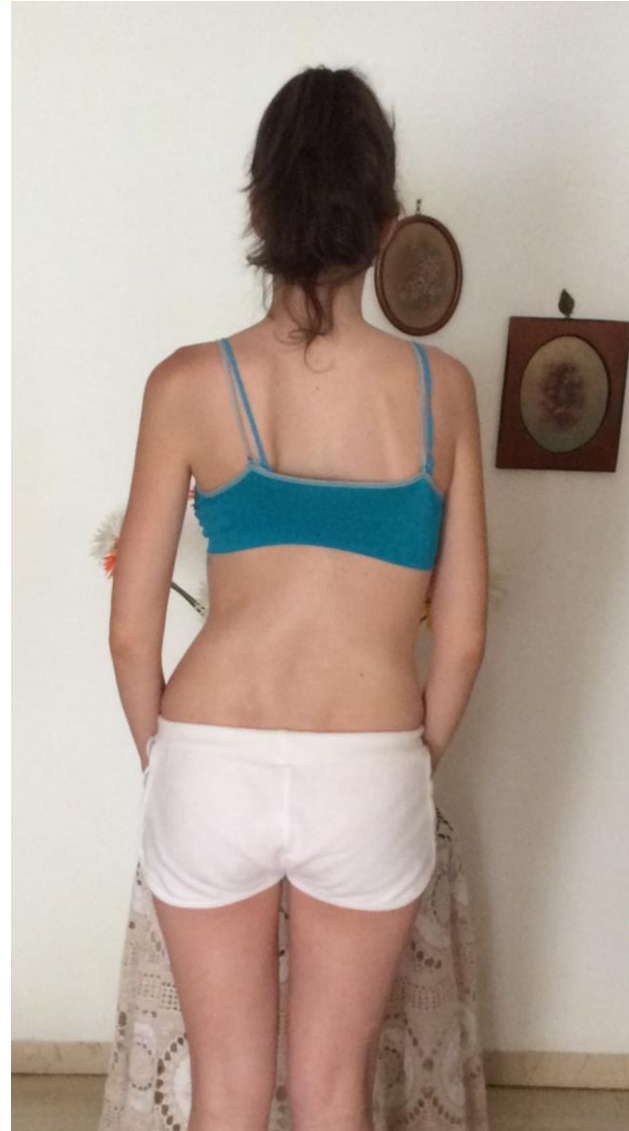Pre-op



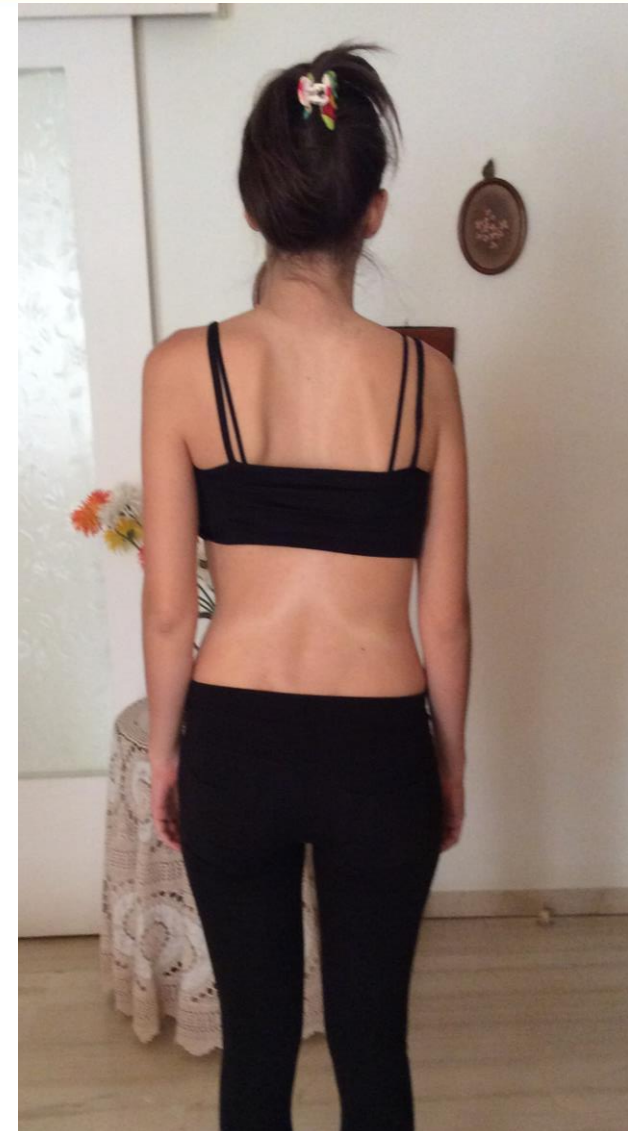3 months post-op

Case study 7 – planned for operation

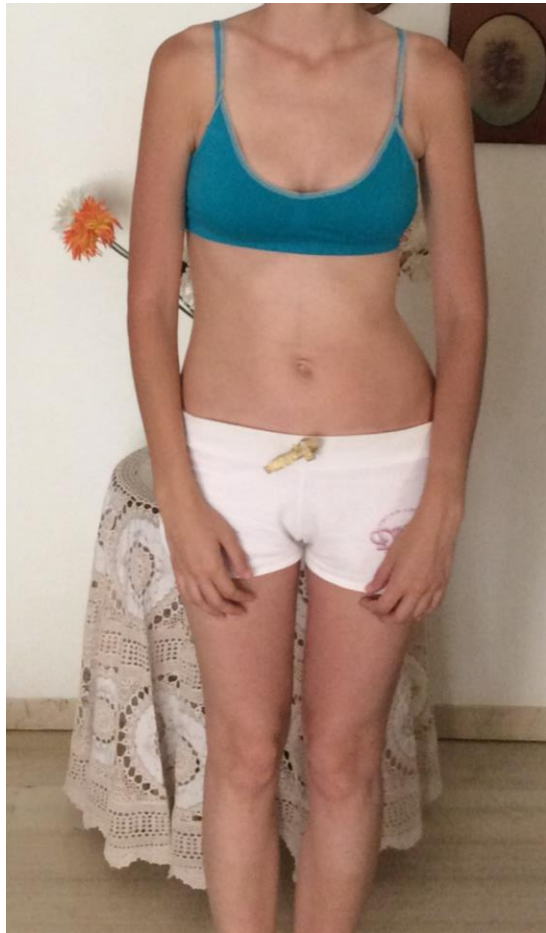



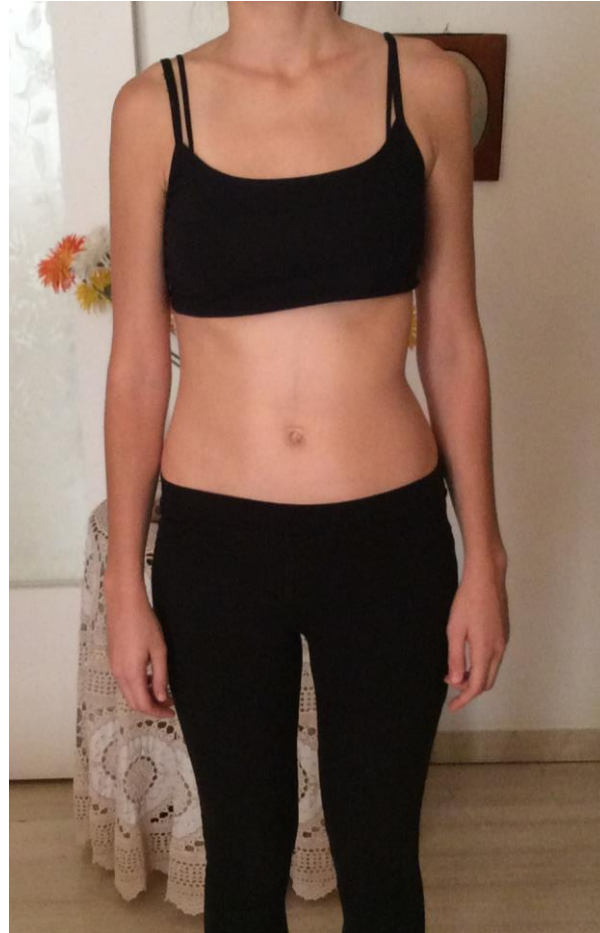Pre-ex



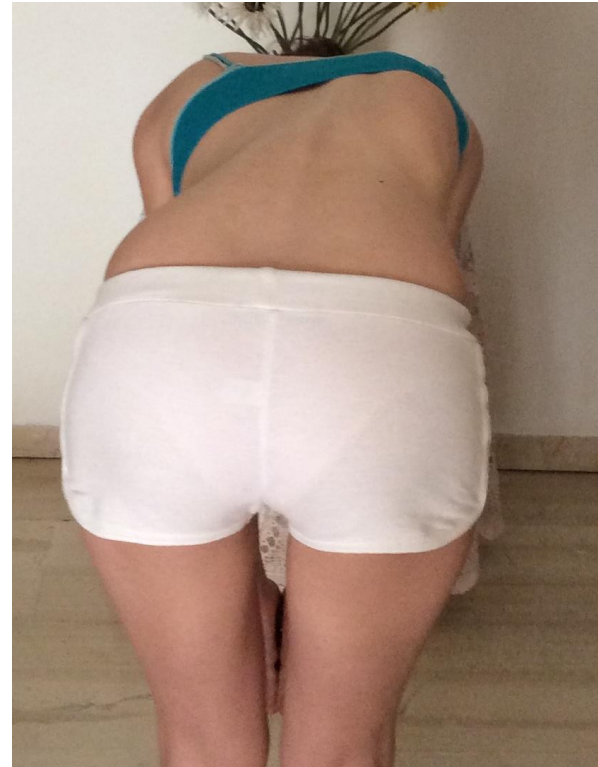2 months post-ex




Pre-ex



2 months post-ex



Pre-ex



2 months post-ex

- ApiFix system can offer an alternative treatment option for some scoliotic patients (not designed for every type of scoliosis)
- Schroth exercises improved Cobb angle, ATR, clinical appearance and pain
- Schroth exercises have clearly better results than the simple side-bending exercises and must always be applied pre and post operation

- More strict application of the initial ApiFix indications (concerns about lumbar scoliosis and double curves)
- Patients operated below 40° (SRS guidelines??), potentially unnecessary risks
- Take into consideration other than only radiological parameters (pain, QoL, patient satisfaction, self-image, psychology, function) to judge the success or fail of ApiFix treatment
- Longer follow-up is needed to determine the long-term results
- Refer the patients to Physiotherapists specialized in scoliosis treatment

- Strong scientific evidence for the effectiveness of Schroth exercises (PSSE) in scoliosis treatment (Level of Evidence I)
- PSSE are clearly superior than general exercises, according to the literature and published guidelines
- 3-dimensional treatment, ATR improvement by Schroth exercises, better cosmetical result
- ADL training reduce mechanical loads, secure the long-term maintenance of the result
- Simple side-bending exercises not suitable for patients with ApiFix on lumbar curve or for patients with double curves

Thank you for your attention



ApiFix

Nikos Karavidas, MSc, PT

*Certified Schroth Therapist (BSPTS)
Certified Schroth Best Practice Therapist
Certified SEAS Therapist
Certified McKenzie Therapist
MSc Sports Physiotherapy, Cardiff University*